



PRESENTING CLINICAL SIGNS

History: Grade 3-4/6 intermittent systolic murmur. Pre-anesthetic evaluation (dental).

DATE

12/9/21

ECHOCARDIOGRAPHIC FINDINGS

2D, M-mode, and Doppler study.

PERFORMED BY:

Dr. Ebersole

Left atrial size is normal. The mitral valve is normal. Left ventricular dimensions are normal, as is left ventricular systolic function. The aorta and aortic appear normal, though there is mildly increased flow velocity in the ascending aorta. Right atrial and right ventricular dimensions are normal. The tricuspid valve is normal. The pulmonary artery and pulmonic valve are normal. No heartworms are visualized. No pericardial effusion or cardiac masses are seen.

INTERPRETED BY

Keith Blass, DVM,
MS, DACVIM
(Cardiology)

LA/Ao - 1.37
LVIDd - 19.4 mm
LVIDs - 11.2 mm
FS - 42%
RA - 21.7 mm
LVOT - 1.50 m/s
RVOT - 1.23 m/s

PATIENT

Kyle Tinson

ASSESSMENT/RECOMMENDATIONS

Normal echocardiogram

SPECIES

Canine

This examination demonstrates no evidence of structural heart disease. Kyle's murmur appears to be due to the presence of mildly increased flow velocity in his aorta, which is a common reason for a functional/innocent murmur to develop in dogs.

BREED

Chihuahua

No therapy is recommended based on this exam, and there are no contraindications to the use of any anesthetic agents.

A recheck echocardiogram is recommended if the characteristics of Kyle's murmur change, or if other new physical exam and/or clinical abnormalities suggestive of cardiac dysfunction develop.

SEX

MN

AGE

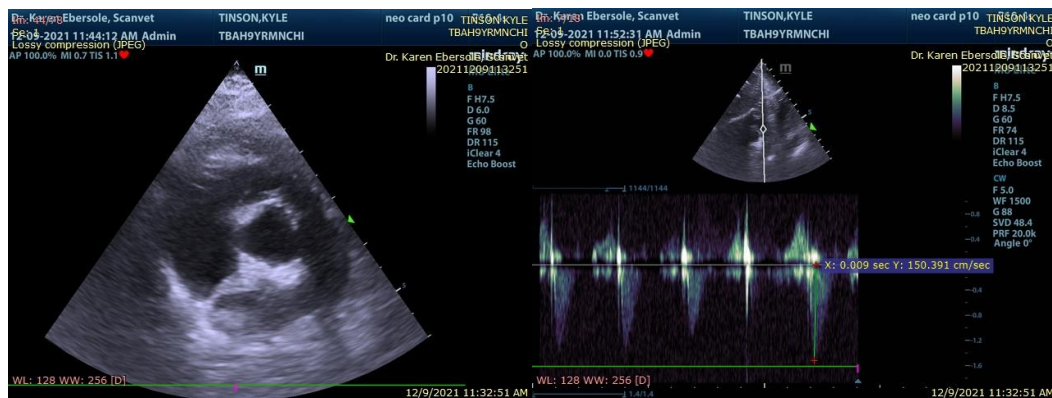
9 y

WEIGHT

8.9 lb

HOSPITAL NAME

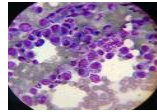
Scanvet



The information and recommendations provided are based on the images presented by the referring veterinarian. No evaluation can be communicated regarding pathology that was not

REFERRING VET

Dr. Sanders



visible in the image/video clips provided.

DATE

Thank you for this referral. If the clinical or image interpretation does not parallel your findings or if I can be of any further assistance please contact me.

12/9/21

PERFORMED BY:

Keith Blass, DVM, MS, DACVIM (Cardiology)
KeithBlass@gmail.com
631-804-5754

Dr. Ebersole

INTERPRETED BY

Keith Blass, DVM,
MS, DACVIM
(Cardiology)

PATIENT

Kyle Tinson

SPECIES

Canine

BREED

Chihuahua

SEX

MN

AGE

9 y

WEIGHT

8.9 lb

HOSPITAL NAME

Scanvet

REFERRING VET

Dr. Sanders